



Revista CEFAC  
ISSN: 1516-1846  
revistacefac@cefac.br  
Instituto Cefac  
Brasil

Lopes de Castro Martinelli, Roberta; Queiroz Marchesan, Irene; Berretin-Felix, Giédre  
ESTUDO LONGITUDINAL DAS CARACTERÍSTICAS ANATÔMICAS DO FRÊNULO LINGUAL  
COMPARADO COM AFIRMAÇÕES DA LITERATURA  
Revista CEFAC, vol. 16, núm. 4, julio-agosto, 2014, pp. 1202-1207  
Instituto Cefac  
São Paulo, Brasil

Available in: <http://www.redalyc.org/articulo.oa?id=169332210019>

- How to cite
- Complete issue
- More information about this article
- Journal's homepage in redalyc.org

redalyc.org

Scientific Information System  
Network of Scientific Journals from Latin America, the Caribbean, Spain and Portugal  
Non-profit academic project, developed under the open access initiative

# LONGITUDINAL STUDY OF THE ANATOMICAL CHARACTERISTICS OF THE LINGUAL FRENULUM AND COMPARISON TO LITERATURE

## *Estudo longitudinal das características anatômicas do frênulo lingual comparado com afirmações da literatura*

Roberta Lopes de Castro Martinelli <sup>(1)</sup>, Irene Queiroz Marchesan<sup>(2)</sup>, Giédre Berretin-Felix<sup>(3)</sup>

### ABSTRACT

**Purpose:** to assess the anatomical characteristics of lingual frenulum in infants at first, sixth and twelfth months of life and compare the findings to the statements found in the literature. **Methods:** video recordings of the lingual frenulum – normal or altered – of 71 infants, from both genders at the first, sixth and twelfth months of life were taken. The recordings were analyzed by two specialists in orofacial motricity who observed the following anatomical aspects: thickness, attachment to the tongue and attachment to the floor of the mouth. The data collected were compared to the literature. **Results:** of the 71 infants, the lingual frenulum of 51 infants was thin and 20 had thick lingual frenulum. 40 infants had the lingual frenulum attached to the middle of the tongue, 27 had the attachment between the apex and the middle of the tongue, and 4 to the apex. Concerning attachment to the floor of the mouth, the lingual frenulum of 42 infants was attached to the alveolar crest and 29 had the attachment between the sublingual caruncles. The characteristics of the lingual frenulum observed at the first, sixth and twelfth months of life remained the same. **Conclusion:** contrary to what has been stated in the literature changes concerning lingual frenulum thickness, attachment to the tongue and to the floor of the mouth were not observed in the 71 infants during the first year of life.

**KEYWORDS:** Lingual Frenulum; Anatomy; Tongue

### ■ INTRODUCTION

Anatomical variations of the lingual frenulum are a controversial subject among the different groups of healthcare professionals and poorly described in the literature. The lack of agreement may lead to inadequate diagnosis and treatment. The literature reports that lingual frenulum in newborns connects the apex of the tongue to the inferior alveolar crest, and that during bone development and growth it moves to the tongue's underside midline – its final position<sup>1-2</sup>. Some authors also state that during

growth the lingual frenulum may stretch or undergo a spontaneous rupture; therefore, the frenulum alteration diagnosis should not be carried out before five years of age<sup>3-5</sup>. Additionally, the literature reports the presence of a hypertrophic lingual frenulum in infants that hinders the movements of the tongue. Some authors state that during the infant's development hypertrophic lingual frenulum becomes thinner allowing free tongue movements<sup>6</sup>. Some studies claim that the severity and functional effects of the lingual frenulum tend to decrease with time and orofacial growth due to the fact that during the first 5 years of life the shape and size of the oral cavity change significantly. The lingual frenulum may recede, stretch, and even undergo spontaneous rupture. Therefore, as the child grows, the severity of the tongue-tie lessens and the initial restrictions of the tongue movements diminish<sup>7</sup>. Other authors state that in infants there is a small fold of membrane

<sup>(1)</sup> Faculty of Odontology, University of São Paulo - Bauru, SP, Brazil.

<sup>(2)</sup> CEFAC, Saúde e Educação, São Paulo, SP - Brazil.

<sup>(3)</sup> Department of Speech-Language Pathology, Faculty of Odontology University of São Paulo- Bauru, SP, Brazil.

Conflict of interest: non-existent

that extends from tongue to mandible's inner surface. Such membrane maintains the tongue in correct position during breastfeeding. After some days of infant's development the membrane is transformed into lingual frenulum, modifying its insertion. Therefore the child will be able to stretch the tongue forward. In some cases, the membrane becomes thicker and shorter and the tip of the tongue is confined, causing ankyloglossia<sup>8-10</sup>. However, these statements do not correspond to the findings observed in infants during their development. Longitudinal studies describing the possible lingual frenulum changes during the first year of life were not found in the literature. Recent studies claim that the anatomical variations of the lingual frenulum are the result of lingual frenulum cells that did not undergo apoptosis completely during the embryological development. The residual tissue may restrain the movements of the tongue<sup>11-13</sup>. From this point of view it is possible to understand the great anatomical variation of lingual frenulum. Recent studies state that the thickness and the attachment of the lingual frenulum to the tongue and to the floor of the mouth do not change during the first six months of life<sup>14</sup>. Histological studies have demonstrated that the lingual frenulum does not undergo rupture and does not stretch due to its histological structure<sup>15</sup>.

The aim of this research was to assess the anatomical characteristics of lingual frenulum – normal or altered – in infants at first, sixth and twelfth months of life and compare the findings to the statements found in the literature.

## ■ METHODS

This was a longitudinal study including 71 full-term infants of both genders. Prematurity, cranio-facial anomalies, and visible genetics syndromes were the exclusion criteria.

A Speech-Language Pathologist (SLP) assessed and video recorded the lingual frenulum – normal or altered – of the infants at the first, the sixth and

twelfth months of life using the lingual frenulum protocol proposed by Martinelli et al 2012 for the assessment<sup>16</sup>.

The video-recordings were evaluated by two SPLs experienced in lingual frenulum assessment. Thickness, attachment to the tongue and to the floor of the mouth were the anatomical aspects considered for analysis.

The classifications of the lingual frenulum were: a) thickness – thin or thick; b) attachment to the tongue – to the midline of the tongue, between the apex and the midline of the tongue, or to the apex; c) attachment to the floor of the mouth – visible from the sublingual caruncles or attached to the alveolar crest.

The data collected were compared to the literature.

The study was approved by the Committee of Ethics in Research of CEFAC, under No. 019-10.

## ■ RESULTS

Of the 71 infants, 16 (22,5%) had lingual frenulum alteration and were referred to frenotomy. Due to several reasons such as parental consent and waiting lines for the procedure, the surgery was not performed until 12 months of age.

Of the 71 infants, the lingual frenulum of 51 infants was thin and 20 had thick lingual frenulum. 40 infants had the lingual frenulum attached to the midline of the tongue, 27 had the attachment between the apex and the midline of the tongue, and 4 to the apex. Concerning attachment to the floor of the mouth, the lingual frenulum of 42 infants was attached to the alveolar crest and 29 had the attachment between the sublingual caruncles (Table 1).

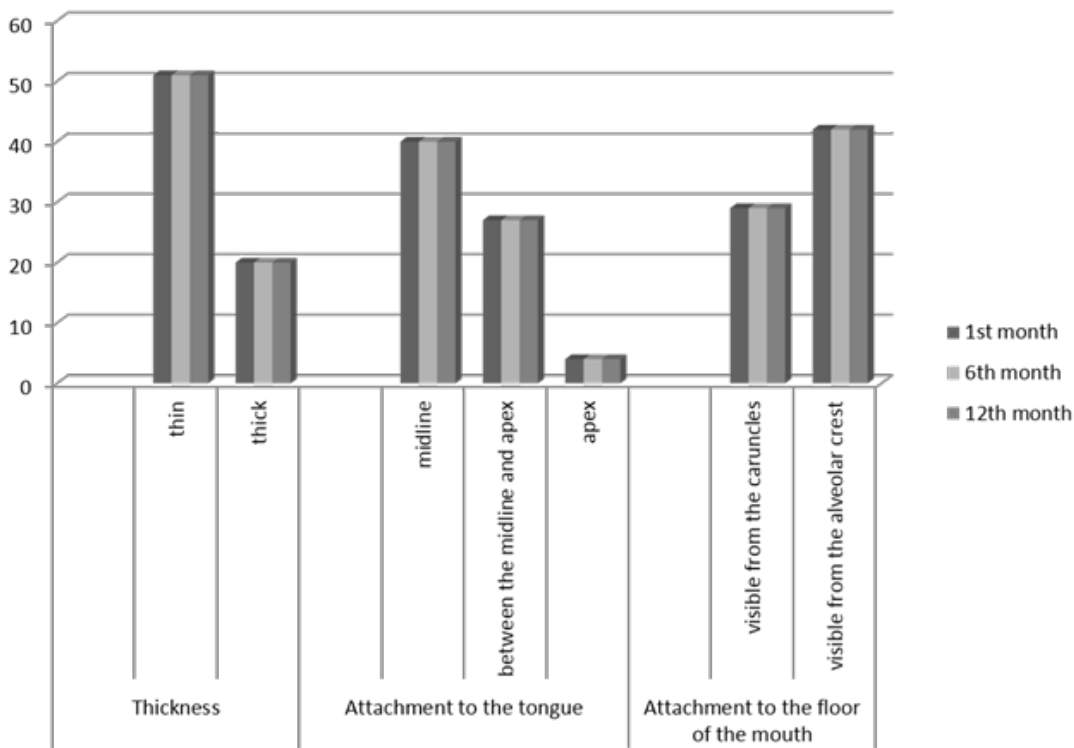
The anatomical characteristics of lingual frenulum – thickness, attachment to the tongue and to the floor of the mouth – observed at the first, sixth and twelfth months of life remained the same (Figure 1).

**Table 1 - Anatomical characteristics of the lingual frenulum of 71 infants assessed at the first month of life**

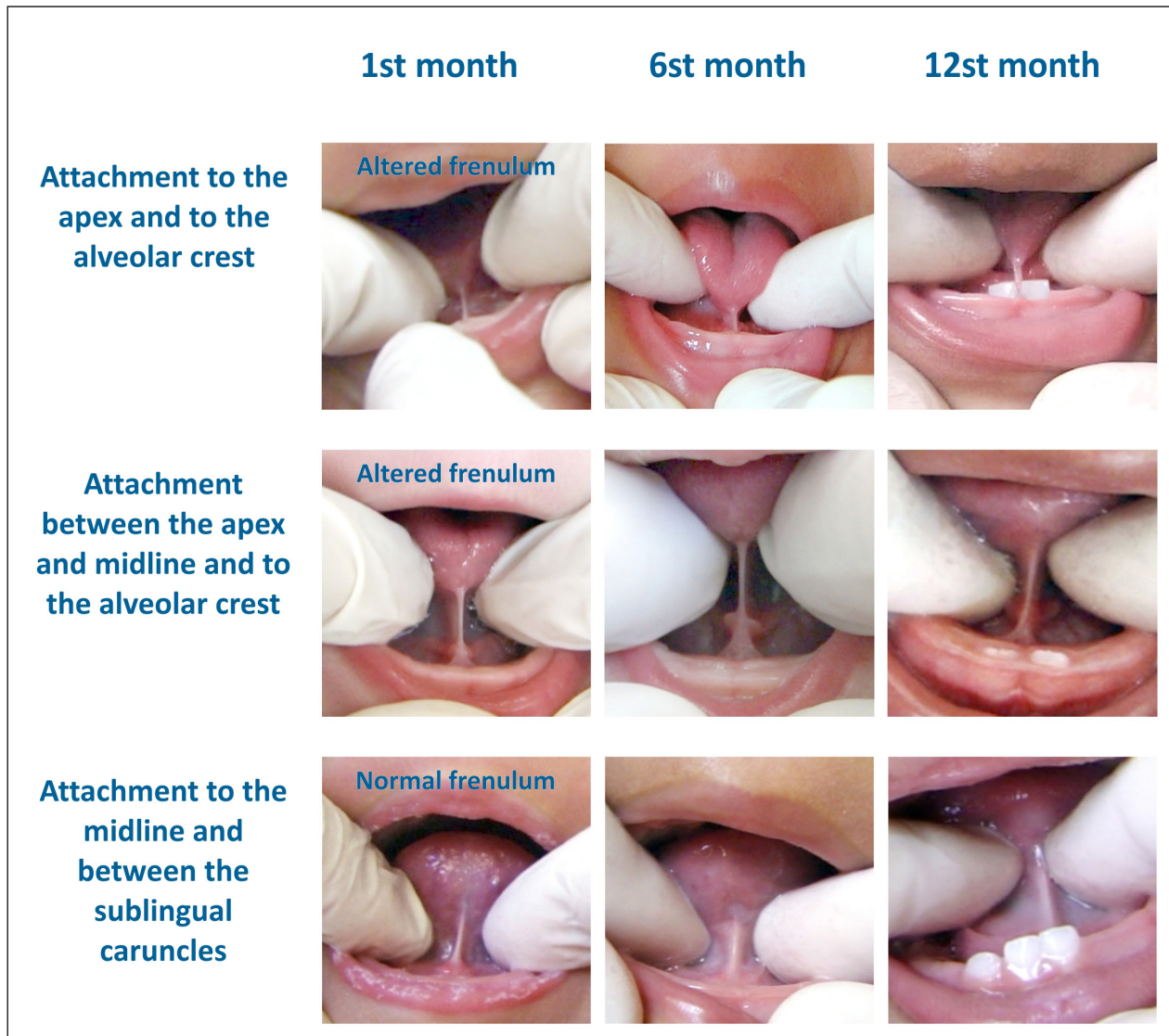
Anatomical characteristics of the lingual frenulum	n
<b>Thickness</b>	
thin	51
thick	20
<b>Attachment to the tongue</b>	
midline	40
between the midline and apex	27
apex	4
<b>Attachment to the floor of the mouth</b>	
visible from the caruncles	29
visible from the alveolar crest	42

Contrary to what the literature reports, the results of the longitudinal study demonstrated that changes concerning lingual frenulum thickness<sup>3-10</sup>,

attachment to the tongue and to the floor of the mouth<sup>1-2</sup> did not occur during the first year of life (Figure 2).



**Figure 1 – Comparison of the anatomical characteristics of the lingual frenulum of 71 infants assessed at the 1<sup>st</sup>, 6<sup>th</sup>, and 12<sup>th</sup> months of life**



**Figure 2 – Anatomical characteristics of the lingual frenulum at the 1<sup>st</sup>, 6<sup>th</sup>, and 12<sup>th</sup> months of life**

■ **DISCUSSION**

Due to absence of longitudinal studies describing the possible lingual frenulum changes during the first year of life, the literature is controversial and non-evidence based<sup>1-10</sup>.

Recent studies claim that the anatomical variations of the lingual frenulum are the result of lingual frenulum cells that did not undergo apoptosis completely during the embryological development. The residual tissue may restrain the movements of the tongue<sup>11-13</sup>. Alterations in orofacial functions – sucking, chewing, swallowing and speech – may be caused by the restriction of tongue movements.

Several authors report that the lingual frenulum alterations interfere with breastfeeding, being one

of the possible causes for breastfeeding problems. Immediate frenotomy is then indicated<sup>11,15-28</sup>. In contrast, other authors state that the lingual frenulum may change until five years of age; therefore, surgery is not indicated before that age<sup>1-10</sup>.

This longitudinal study demonstrated that changes in the lingual frenulum – normal or altered<sup>16</sup> – concerning thickness, attachment to the tongue and to the floor of the mouth were not observed in the 71 infants assessed at the first, sixth and twelfth months of age.

Although some authors state that during growth the lingual frenulum may stretch or undergo a spontaneous rupture; therefore, the frenulum alteration diagnosis should not be carried out before five years of age<sup>3-5</sup>, the study demonstrated that the anatomical characteristics of the lingual frenulum

remained the same during growth and development at the first year; therefore, we may infer that the lingual frenulum will not change in the following years. For this reason, waiting until 5 years of age to diagnose and indicate surgery or therapy, as the literature suggests, may interfere with breastfeeding and development of oral functions.

Future longitudinal studies including children until 5 years of age may contribute with data that confirm the findings of this study.

As soon as the restriction of tongue movements is diagnosed proper treatment should be indicated mainly to avoid untimely weaning<sup>11,13-28</sup>.

## ■ CONCLUSION

Contrary to what has been stated in the literature changes concerning lingual frenulum thickness, attachment to the tongue and to the floor of the mouth were not observed in the 71 infants during the first year of life.

## RESUMO

**Objetivo:** avaliar características anatômicas do frênulo lingual de bebês no 1º, no 6º e no 12º mês de vida, comparando os achados com a literatura. **Métodos:** foram realizados registros audiovisuais de frênulos linguais, normais ou alterados, de 71 bebês, de ambos os gêneros, no 1º, no 6º e no 12º mês de vida. Esses registros foram analisados por duas especialistas em motricidade orofacial considerando os seguintes aspectos anatômicos do frênulo lingual: espessura, fixação na língua e fixação no assoalho da boca, comparando esses dados com o que é citado na literatura. **Resultados:** dos 71 bebês avaliados, 51 deles apresentaram frênulo com espessura delgada e 20 espessa. 40 bebês apresentaram fixação do frênulo no terço médio da língua; 27 entre o ápice e o terço médio da língua e 4 no ápice. Quanto à fixação no assoalho da boca, 42 bebês apresentaram a fixação do frênulo na crista alveolar inferior e 29 entre as carúnculas sublinguais. As características de todos os frênulos linguais observadas no 1º, no 6º e 12º mês de vida permaneceram as mesmas. **Conclusão:** quanto à espessura, fixação na língua e fixação no assoalho da boca, o frênulo lingual dos 71 bebês examinados não se modificou durante o primeiro ano de vida, contrapondo-se à literatura.

**DESCRITORES:** Freio Lingual; Anatomia; Língua

## ■ REFERÊNCIAS

1. Navarro NP, López M. Anquiloglossia en niños de 5 a 11 años de edad. Diagnóstico y tratamiento. *Rev Cubana Estomatol.* 2002;39:3-7.
2. Correia MSNP. Odontopediatria na primeira infância. 3. ed. São Paulo: Santos; 2009. p. 942.
3. Wright JE. Tongue-tie. *J Paediatr Child Health.* 1995;31:276-8.
4. Wallace AF. Tongue-tie. *Lancet.* 1963;2:377-8.
5. Wallace AF. The tongue-tie controversy. *Nurs Times.* 1964;60:527-8.
6. Mazzochi A, Clini F. La brevitádelfrenulolinguale: cosiderazioncliniche e terapeutiche. *Pediatr Med Chir.* 1992;14:643-6.
7. Kummer AW. Ankyloglossia: To Clip or Not to Clip? That's the Question. *The ASHA Leader.* 2005; December 27.
8. Moss SJ. Crescendo sem cárie. São Paulo: Quintessence; 1996.
9. Usberti AC. Odontopediatria clínica. São Paulo: Santos; 1991.
10. Walter L, Ferelle A, Issao M. Odontologia para o bebê. São Paulo: Artes Médicas; 1996.
11. Knox I. Tongue Tie and Frenotomy in the Breastfeeding Newborn. *NeoReviews* 2010; 11(9):513-9.
12. Morita H, Mazerbourg S, Bouley DM, et al. Neonatal lethality of LGR5 null mice is associated with ankyloglossia and gastrointestinal distension. *Mol Cell Biol.* 2004;24:9736-43.
13. Karahan S, CinarKul B. Ankyloglossia in dogs: a morphological and immunohistochemical study. *AnatHistolEmbryol.* 2009;38:118-21.
14. Martinelli RLC, Marchesan IQ, Gusmão RJ, Berretin-Felix G, Rodrigues AC. Características histológicas do frênulo lingual em humanos. In: XX Congresso Brasileiro de Fonoaudiologia, Brasília. *Revista da Sociedade Brasileira de Fonoaudiologia – Suplemento especial.* 2012.

15. Martinelli RLC, Marchesan IQ. Frênulo lingual nos primeiros meses de vida. In: XX Congresso Brasileiro de Fonoaudiologia, Brasília. Revista da Sociedade Brasileira de Fonoaudiologia – Suplemento especial. 2012.
16. Martinelli RLC, Marchesan IQ, Berretin-Felix G. Lingual Frenulum Protocol with scores for infants. *Int J Orofacial Myology*. 2012;38:104-12.
17. National Institute for Health and Clinical Excellence. Interventional Procedure Guidance 149. Division of Ankyloglossia (Tongue-tie) for breastfeeding. [www.nice.org.uk](http://www.nice.org.uk) (acesso em novembro 2011).
18. Hall DMB, Renfrew MJ. Tongue tie. *Arch Dis Child* 2005;90:1211-5.
19. Dollberb S, Botzer E, Grunis E, et al. Immediate nipple pain relief after frenotomy in breast-fed infants with ankyloglossia: a randomised, prospective study. *J PediatrSurg* 2006;41:1598-600.
20. Berry J, Griffiths M, Westcott C. A double-blind, randomized, controlled trial of tongue-tie division and its immediate effect on breastfeeding. *Breast Med* 2011;0:1-5.
21. Buryk M, Bloom D, Shope T. Efficacy of Neonatal Release of Ankyloglossia: A Randomized Trial. *Pediatrics* 2011;128:280-8.
22. Edmunds J, Hazelbaker A, Murphy JG, Philipp BL. Roundtable discussion: tongue-tie. *J Hum Lact* 2012;28:114-7.
23. Cho A, Kelsberg G, Safranek S. When should you treat tongue-tie in a newborn? *JFPONLINE.COM* 2010;59(12):712a-b.
24. Forlenza GP, Black NMP, McNamara EG, Sullivan SE. Ankyloglossia, Exclusive Breastfeeding, and Failure to Thrive. *Pediatrics* 2010;125:e1500-4.
25. Constantine AH, Williams C, Sutcliffe AG. A systematic review of frenotomy for Ankyloglossia (tongue tie) in breast fed. *Infants Arch Dis Child* 2011;A62 96(Suppl 1):A1–A100.
26. Edmunds J, Miles S, Fulbrook P. Tongue-tie and breastfeeding: a review of the literature. *BreastRev* 2011;19(1):19-26.
27. Martinelli RLC. Relação entre as características anatômicas do frênulo lingual e as funções de sucção e deglutição em bebês. Dissertação de mestrado. Universidade de São Paulo. 2013.
28. Miranda BH, Milrou CJ. A quick snip e A study of the impact of outpatient tongue tie release on neonatal growth and breastfeeding. *J PlastReconstAesthSurg* 2010; 63:e683-5.

Received: June 02, 2013  
Accepted: August 28, 2013

Mailing address:  
Roberta Lopes de Castro Martinelli  
Av. Angelo Piva, 331 – Brotas – São Paulo  
CEP: 17380-000  
E-mail: [robertalcm@gmail.com](mailto:robertalcm@gmail.com)